

This Page Is Inserted by IFW Operations  
and is not a part of the Official Record

## **BEST AVAILABLE IMAGES**

Defective images within this document are accurate representations of the original documents submitted by the applicant.

Defects in the images may include (but are not limited to):

- BLACK BORDERS
- TEXT CUT OFF AT TOP, BOTTOM OR SIDES
- FADED TEXT
- ILLEGIBLE TEXT
- SKEWED/SLANTED IMAGES
- COLORED PHOTOS
- BLACK OR VERY BLACK AND WHITE DARK PHOTOS
- GRAY SCALE DOCUMENTS

**IMAGES ARE BEST AVAILABLE COPY.**

**As rescanning documents *will not* correct images,  
please do not report the images to the  
Image Problem Mailbox.**

STIC-ILL

NOV/14

From: Canella, Karen  
Sent: Wednesday, May 14, 2003 3:05 PM  
To: STIC-ILL  
Subject: ill order 09/230,955

445778

Art Unit 1642 Location 8E12(mail)

Telephone Number 308-8362

Application Number 09/230,955

1. American Journal of Pathology:  
1993 Feb, 142(2):403-412  
1993, 143(4):1150-1158  
1984, 114(3):454-460  
1996, 148(3):865-875  
1965 Sep, Vol. 44, pp. 280-282
2. Cancer Research, 1993 May 15, 53(10 suppl):2287-2299
3. Cancer epidemiology, biomarkers and Prevention, 1996 Jul, 5(7):549-557
4. Lab Investigation:  
1980, 42(1):91-96  
1988, 58(2):141-149
5. Gynecol Oncol, 1982, 13(1):58-66
6. International Journal of Gynecological Pathology:  
1985, 4(4):300-313  
1986, 5(2):151-162  
1992, 11(1):24-29
7. Differentiation:  
1986, 31(3):191-205  
1988, 39(3):185-196
8. Cancer (Phila), 1989, 63(7):1337-1342
9. Cancer Res, 1990, 50(16):5143-5152
10. Virchows Arch B Cell Pathol Incl Mol Pathol, 1987, 54 (2):98-110
11. Acta Histochemica et Cytochemica:  
~~1994, 27(3):251-257~~  
1996, 29(1):51-56
12. Archives of Gynecology and Obstetrics, 1989, 246(4):233-242
13. Clin Lab Med, 1995 Sep, 15(3):727-742
14. Clin Obstet Gynaecol, 1984 Apr, 11 (1):5-23

Car

Acta Histochem. Cytochem. Vol. 29 No. 1 51-56 (1996)  
 Department of Obstetrics and Gynecology, Yamanashi Medical College, Yamanashi 409-38  
 received

Acta Histochem. Cytochem. Vol. 29 No. 1 51-56 (1996)

## Keratin Expression in Normal Cervical Epithelium, Cervical Intraepithelial Neoplasia and Cervical Cancer

Atsushi Ikegami and Junzo Kato

Department of Obstetrics and Gynecology, Yamanashi Medical College, Yamanashi 409-38

Received for publication March 15, 1996 and in revised form May 30, 1996

We have studied the keratin expression in normal and abnormal uterine cervix using the immunohistochemical method. Six commercially available keratin antibodies (M 630, CAM 5.2, RKSE 60, 1C 7, LL 002 and RCK 108) were used to stain the cervical tissues. CAM 5.2 reacted with the immature metaplasia strongly and the mature metaplasia weakly. 1C 7 and LL 002 reacted with the mature metaplasia strongly, compared to their reactivities in immature metaplasia. These results supported the idea that when reserve cells transform into squamous metaplasia, keratin 8 ceases to be expressed, and the synthesis of keratins 13 and 14 is

initiated. The expression of keratin 8 was increased up to 77% of CIN III, compared to 15% of CIN I and II. About 90% of the squamous cell carcinoma contained keratin 8. Based on this observation, we hypothesized that the CIN lesions with expression of keratin 8 are progressive into cervical cancer. With respect to the keratin expression of endocervical adenocarcinoma, keratins 8 and 19 were found in all the cases, although keratins 5, 10, 13 and 14 were not found. This result indicated that the endocervical adenocarcinoma develops from the columnar cells.

**Key words:** Keratin, Uterine cervix, Immunohistochemistry

### I. Introduction

Keratins comprise a family of at least 20 intermediate filament proteins catalogued from 1 to 20, exhibiting a tissue specific distribution pattern in the epithelia [10, 11]. The 20 members of the keratin family are distinguishable on the basis of their molecular weight, the isoelectric pH, the amino acid sequence, and the immunologic properties [10, 11]. Many studies have shown that the keratin composition of cells varies in different cell types, and in different stages of differentiation or development [11, 12]. Thus, keratins have proved to be efficient tools for characterizing the differentiation of a particular cell type and for establishing the origin of certain cells. The keratin expression patterns in the normal cervix are known to a large extent, using specific monoclonal antibodies against the individual keratin polypeptides [5, 6, 8, 9, 16]. The distribution of the keratins in the normal cervix can be summarized as follows: ectocervical nonkeratinizing

squamous epithelium shows a keratin pattern characterized by intense expression of keratins 4 and 13. In addition, keratins 5, 14 and 19 are detected in the ectocervical basal cell layer. The endocervical columnar cells contain keratins 8, 18 and 19. The endocervical reserve cells contain keratins 5, 8, 14, 18 and 19. This keratin expression indicates that reserve cells have the potential to give rise not only to the squamous epithelial cells but also to the columnar cells.

There have been a few studies with respect to the keratin expression in cervical intraepithelial neoplasia (CIN) and cervical cancer, using specific keratin antibodies [4, 7, 9, 15]. These studies suggest that the keratin expression pattern of these lesions may supply valuable information on whether a CIN lesion is progressive or regressive in nature and CIN lesions expressing keratins 8, 18 and 19 are progressive into carcinoma. The aims of this study are as follows: 1) to summarize the keratin expression in the normal cervix, CIN lesion, and cervical cancer, 2) to analyze whether it is possible to distinguish between a progressive and a regressive CIN lesion based on keratin expression, and 3) to examine whether the endocervical adenocarcinoma are derived from reserve cells.

Correspondence to: Dr. Atsushi Ikegami, Department of Obstetrics and Gynecology, Yamanashi Medical College, 1110 Shimokato, Tamaho, Nakakoma, Yamanashi 409-38, Japan.

## II. Materials and Methods

### Tissues

Uterine tissue was obtained by biopsies or hysterectomy performed on 54 women for cervical dysplasia or cervical cancer at the University Hospital of Yamanashi Medical College. Cervical tissues were fixed in 95% ethanol and embedded in paraffin. Normal ectocervical epithelium was diagnosed in 24 fragments, endocervical columnar cells in 29 fragments, reserve cells in 21 fragments, immature metaplasia in 21 fragments, mature metaplasia in 19 fragments, CIN I in 6 fragments, CIN II in 8 fragments, CIN III in 13 fragments, keratinizing squamous cell carcinoma in 8 fragments, large-cell non-keratinizing squamous cell carcinoma in 14 fragments, adenocarcinoma in 8 fragments.

### Antibodies

Six monoclonal antibodies were used in this study. Their characteristics are summarized in Table 1.

### Immunohistochemistry

Keratin staining was performed using a LSAB (labelled-streptavidin biotin) kit (Dako). Sections were deparaffinized in xylene, rehydrated through alcohol, and then immersed in 3% hydrogen peroxidase in methanol for 10 min to block endogenous peroxidase activity. Sections were subsequently washed in phosphate-buffered saline (PBS), and normal goat serum was applied for 10 min to reduce non-specific antibody binding. The sections were incubated with the appropriately diluted primary antibodies, or with control normal mouse serum for 30 min at room temperature. The biotinylated goat antimouse IgG was used as the linker. After washing, the streptavidin complex was applied, stained with diaminobenzidine and then counterstained with hematoxylin. The stainings were assessed as follows: (+) strongly positive (more than 50% positive cells), (+/-) weakly positive (less than 49% positive cells) and (-) negative.

## III. Results

Each of the antibodies used in this study reacted exclusively with the epithelial cells. The staining pattern in the various components of the normal cervix is summarized in Table 2. The percentage of staining for CAM 5.2 in CIN lesions and cervical carcinoma is shown in Table 3.

Table 1. Antibodies used for the study

Antibody	Keratins recognized	Dilution	Source
M 630	1, 5, 10, 14	1 in 50	Dako
CAM 5.2	8	1 in 10	Becton-Dickinson
RKSE 60	10	1 in 20	Novocastra
1C 7	13	1 in 20	Novocastra
LL 002	14	1 in 10	Novocastra
RCK 108	19	1 in 100	Dako

ed in Table 2. The percentage of staining for CAM 5.2 in CIN lesions and cervical carcinoma is shown in Table 3.

### Squamous epithelium

M 630 (keratins 1, 5, 10 and 14) reacted with all layers of epithelium strongly. 1C 7 (keratin 13) reacted with the parabasal, intermediate, and superficial cells strongly. LL 002 (keratin 14) reacted with the basal and parabasal cells strongly, and with the intermediate cells weakly. Staining with RCK 108 (keratin 19) was uniformly positive in the basal cells (Fig. 1). CAM 5.2 (keratin 8) and RKSE 60 (keratin 10) were negative.

### Columnar cells

All endocervical columnar cells strongly reacted with CAM 5.2 and RCK 108. M 630 (Fig. 2), RKSE 60, 1C 7 and LL 002 were negative.

### Reserve cells

Reserve cells appear in a few of the normal cervical glands as a single layer of cuboidal cells beneath the columnar cells. The majority of the reserve cells were strongly stained with M 630 (Fig. 2), CAM 5.2 and RCK 108, and weakly with LL 002. RKSE 60 and 1C 7 were negative.

### Immature squamous metaplasia

In all the cases, M 630 reacted with all layers strongly. CAM 5.2 (Fig. 3) and RCK 108 reacted with all layers in heterogeneous staining pattern. 1C 7 reacted with a few dispersed cells. LL 002 reacted with all epithelial layers weakly, with exception of the superficial layer. RKSE 60 was negative.

### Mature squamous metaplasia

The pattern of keratin expression was almost identical to that observed in ectocervical squamous epithelium. There was only slight reactivity for CAM 5.2 (Fig. 4). The reactivities for 1C 7 and LL 002, compared to those in immature squamous metaplasia, had increased. RCK 108 reacted with all epithelial layers strongly (Fig. 1).

### CIN I, CIN II

In all the cases, M 630 reacted with all layers strongly. RCK 108 showed focal staining through the whole epithelium in 93% of the cases. 1C 7 reacted with 86% of the cases through the epithelium above the parabasal cells in the uniformly diffuse pattern. LL 002 reacted in all cases with varying intensity, leaving the superficial epithelium negative. RKSE 60 were negative in all the cases. CAM 5.2 reacted with 15% of the cases weakly.

### CIN III

In all the cases, M 630 reacted with all layers strongly. RCK 108 showed homogeneous staining through the whole epithelium in 84% of the cases. 1C 7 reacted with 70% of cases through the epithelium above the parabasal

## Keratin Expression in Abnormal Uterine Cervix

53

Table 2. Reactivity of keratin antibodies in endo- and ectocervical cells

	M 630	CAM 5.2	RKSE 60	1C 7	LL 002	RCK 108
Columnar cells	-	+	-	-	-	+
Reserve cells	+	+	-	-	+/-	+
Immature metaplasia	+	+	-	+/-	+/-	+
Mature metaplasia	S	+	-	-	+	+
	I	+	+/-	-	+	+
	PB	+	+/-	-	+	+
	B	+	+/-	-	-	+
Squamous epithelia	S	+	-	-	+	-
	I	+	-	-	+	+/-
	PB	+	-	-	+	-
	B	+	-	-	-	+

Abbreviation: S=superficial cells, I=intermediate cells, PB=parabasal cells, B=basal cells  
Intensity: (+) strongly positive, (+/-) weakly positive, (-) negative

Table 3. The percentage of staining for CAM 5.2 in CIN lesions and cervical carcinoma

Type of lesion	Staining for CAM 5.2 (%)
Normal ectocervix [N=24]	0
CIN I, CIN II [N=14]	15
CIN III [N=13]	77
Squamous cell carcinoma keratinizing type [N=8]	88
Large-cell nonkeratinizing type [N=14]	93
Endocervical adenocarcinoma [N=8]	100

cells in the uniformly diffuse pattern. LL 002 reacted with varying intensity through the whole epithelium in 77% of the cases. RKSE 60 were negative in all the cases. CAM 5.2 reacted with 77% of the cases in heterogeneous staining pattern (Fig. 5).

**Keratinizing squamous cell carcinoma**

In all the cases, M 630, RCK 108, LL 002 and 1C 7 were shown with various staining patterns. LL 002 was positive in the basal cell compartment, which tended to decrease toward the inner cell compartment. 1C 7 revealed only partial positivity in the inner cell compartment. RKSE 60, a marker for keratinization, was shown in dispersed cells in the inner cell compartment in 88% of the cases. CAM 5.2 reacted with 88% of the cases in heterogeneous staining pattern (Fig. 6).

**Large-cell nonkeratinizing squamous cell carcinoma**

In all the cases, M 630, RCK 108, LL 002 and 1C 7

were shown with various staining patterns. The staining patterns were almost identical to that observed in keratinizing carcinoma. RKSE 60 was positive in 15% of the cases. CAM 5.2 reacted with 93% of the cases in heterogeneous staining pattern.

**Endocervical adenocarcinoma**

In all the cases, CAM 5.2 and RCK 108 were positive strongly, M 630, 1C 7, LL 002 and RKSE 60 were negative.

**IV. Discussion**

We analyzed the expression of keratin in normal cervix, CIN lesions, and cervical cancer using a panel of antibodies directed against keratins. Previous studies done by us and others showed the superiority of ethanol over formalin as a fixative for the demonstration of keratins [2, 6].

**Ecto- and endocervical epithelium**

The reserve cells reacted with M 630 (keratin 1, 5, 10 and 14), CAM 5.2 (keratin 8) and RCK 108 (keratin 19) strongly. Endocervical columnar cells reacted with CAM 5.2 (keratin 8) and RCK 108 (keratin 19) strongly, but did not react with M 630 (keratins 1, 5, 10 and 14). This comparison of keratin expression between reserve cells and endocervical columnar cells showed that keratins 8 and 19 found in reserve cells were also found in columnar cells. As endocervical columnar cells belong to the end stage of differentiation, these results indicated that these cells are derived from reserve cells, most of which lost expression of keratins 1, 5 and 14 during differentiation into columnar cells.

**Squamous metaplastic epithelium**

We also were able to show how the keratin expression change when reserve cells differentiated from reserve cell hyperplasia through immature squamous metaplasia to



Fig. 1. RCK 108 (keratin 19) reacts with basal cells in squamous epithelium (left side) and all layers in mature metaplasia (right side).  $\times 100$ .




Fig. 4. Mature squamous metaplastic cells are stained weakly with CAM 5.2 (keratin 8).  $\times 100$ .

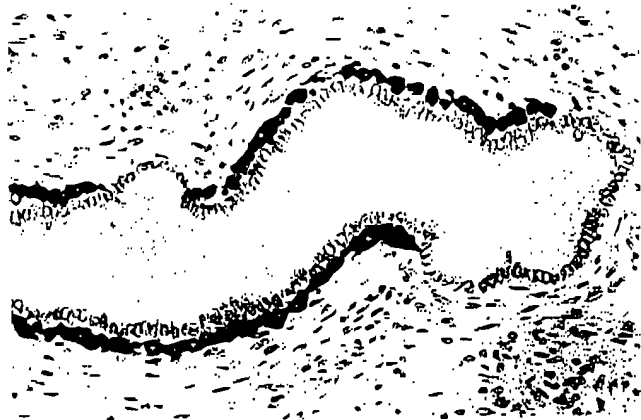

Fig. 2. Reserve cells are stained strongly with M 630 (keratins 1, 5, 10 and 14). Columnar cells show no reaction.  $\times 150$ .




Fig. 5. CIN III shows heterogeneous staining pattern with CAM 5.2 (keratin 8).  $\times 150$ .



Fig. 3. Immature squamous metaplastic cells are stained with CAM 5.2 (keratin 8) in heterogeneous pattern. Columnar cells are stained strongly with CAM 5.2.  $\times 150$ .




Fig. 6. Keratinizing squamous cell carcinoma is stained strongly with CAM 5.2 (keratin 8).  $\times 150$ .

mature squamous metaplasia. Smedts *et al.* [15] showed that the differentiation into squamous metaplasia is followed by the loss of keratins 8 and 18 and a high content of keratins 5, 6, 14, 15 and 16, which are normally found in the squamous epithelium. In our study, CAM 5.2 (keratin 8), which normally is found in the simple epithelium like columnar cells, reacted with the immature metaplasia strongly and the mature metaplasia weakly. Furthermore, 1C 7 (keratin 13) and LL 002 (keratin 14) reacted with the mature squamous metaplasia strongly, compared to their reactivities in immature squamous metaplasia. These results supported the idea that when reserve cells proliferate and transform into squamous metaplasia, keratin 8 found in endocervical columnar cells ceases to be expressed, and the synthesis of keratins found in squamous epithelium, such as keratins 13 and 14, is initiated. Based on these observation, we consider reserve cells to be a common progenitor of both the squamous metaplasia and the endocervical columnar cells. The striking observation is the expression of keratin 19 in mature squamous metaplasia. Previous studies showed that keratin 19 was positive in the basal cells of the mature squamous metaplasia [7, 13, 15, 16]. In this study, RCK 108 (keratin 19) reacted all layers of mature squamous epithelium strongly. We were able to distinguish squamous epithelium from mature squamous epithelium, using antibody RCK 108 (keratin 19).

#### *Cervical intraepithelial neoplasia*

The reserve cells lying below the columnar cells can transform into squamous metaplasia as described above. However, if this differentiation is disturbed by some stimulation, the reserve cells may proliferate into an atypical metaplasia or CIN lesions. It is widely accepted that most cases of CIN I and II regress, while a small percentage show progression to CIN III and cervical cancer. It is important to predict whether CIN lesions progress into cervical cancer or become regressive in nature. The question of whether it is possible to distinguish between a progressive and a regressive CIN lesion based on keratin expression is still open. The comparison of the keratin expression between CIN III and CIN I and II showed a profound difference with regard to the keratin 8 expression. In this study, the expression of keratin 8 (CAM 5.2) was increased up to about 77% of CIN III, compared to 15% of CIN I and II. The positive percentage of keratin 8 expression found in up to 77% of CIN III was considerably higher than that found by Bobrow *et al.* [3] and Angus *et al.* [1], possibly because of the effect of formalin fixation and paraffin embedding. Smedts *et al.* [13, 15] showed that CAM 5.2 (keratin 8) reacted with 50% of CIN III, which were frozen materials. Our study of the keratin expression in CIN lesions showed that keratin 8 (CAM 5.2) was found in a higher percentage of CIN III. About 90% of the squamous cell carcinoma was stained with CAM 5.2 (keratin 8). Based on this observation, it is tempting to

speculate that the CIN lesions with expression of the keratin 8 are progressive into cervical cancer in nature and the CIN lesions without expression of the keratin 8 are regressive in nature or will persist without progression. However, there is a possibility that CIN lesions produce keratin 8 during the progression of these lesions into cervical cancer.

#### *Squamous cell carcinoma*

The keratin phenotype of keratinizing squamous cell carcinoma was very complex, with expression of keratin 8 (CAM 5.2) in 88% of the cases. Keratin 10 (RKSE 60), an ultimate marker for keratinizing, was found in 88% of the cases. In addition, keratins characteristic of nonkeratinizing epithelium, ie, keratins 5, 13, and 14 were found in all the cases. The keratin expression of nonkeratinizing squamous cell carcinoma was almost identical to that observed in keratinizing squamous cell carcinoma, although keratin 10 (RKSE 60) was positive in 15% of the cases. The percentage of CAM 5.2 (keratin 8) staining was as high as that in keratinizing squamous cell carcinoma. In pathological diagnosis, it may be difficult to distinguish a keratinizing squamous cell carcinoma from a nonkeratinizing squamous cell carcinoma. In such a case, keratin antibody RSKE 60 (keratin 10) may be useful. As the keratinizing squamous cell carcinoma is considered to have a poor prognosis, it is important to study the relationship between the keratin expression and the prognosis of squamous cell carcinoma.

#### *Endocervical adenocarcinoma*

Although the origin of the endocervical adenocarcinoma is still unknown, it is generally accepted that this lesion can arise from both the columnar cells and reserve cells. With respect to the keratin expression of endocervical adenocarcinoma, keratin 8 (CAM 5.2) and 19 (RCK 108) were found in all the cases, although keratins 5, 10, 13 and 14 (M 630, RSKE 60, 1C 7 and LL 002) were not found. This keratin expression pattern is similar to that of the columnar cells. Moll *et al.* [11] reported the presence of keratins 7, 8, 17, 18 and 19 in endocervical adenocarcinoma using their gel electrophoretic studies but did not detect keratins 4, 6, 10 and 13. In contrast, Smedts *et al.* [14] reported that all endocervical adenocarcinoma contain keratins 7, 8, 17, and 19, in addition to keratins 5 and 14 in most cases, using immunohistochemical methods. The keratin expression pattern of the endocervical adenocarcinoma is similar to that of the reserve cells. On the basis of these findings, Smedts *et al.* [14] suggested that the endocervical adenocarcinoma does not usually arise from the columnar cells but from the reserve cells. This discrepancy may be explained by the difference in the immunohistochemical procedure and the fixation of materials, ie, frozen or ethanol fixed paraffin embedded. Although the progenitor cells for the endocervical adenocarcinoma are considered to be the columnar cells and the reserve cells, it seems that the endocervical

adenocarcinoma develops from the columnar cells lining the endocervical canal, according to the keratin expression pattern in our study.

## V. Acknowledgments

The authors gratefully acknowledge the excellent technical assistance of Tsutomu Yuminamochi.

## VI. References

1. Angus, B., Kiberu, S., Purvis, J. and Horne, C.H.W.: Cytokeratins in dysplasia and neoplasia: A comparative study of immunohistochemical staining using monoclonal antibodies NCL-5D3, CAM 5.2 and PKK 1. *J. Pathol.* 155; 71-77, 1988.
2. Battifora, H., Kopinski, M.: The influence of protease digestion and duration of fixation on the immunostaining of keratins. A comparison of formalin and ethanol fixation. *J. Histochem. Cytochem.* 34; 1095-1100, 1986.
3. Bobrow, L., Makin, C.A., Law, S. and Bodmer, W.: Expression of low molecular weight cytokeratin proteins in cervical neoplasia. *J. Pathol.* 148; 135-140, 1986.
4. Gernow, A., Nielsen, B., Holund, B. and Clausen, P.P.: Immunohistochemical study of possible changes in keratin expression during neoplastic transformation of the uterine mucosa. *Virchow Arch. [A]* 416; 287-293, 1990.
5. Gigi-Leitner, O., Geiger, B., Levy, R. and Czernoblisky, B.: Cytokeratin expression in squamous metaplasia of the human uterine cervix. *Differentiation* 31; 191-205, 1986.
6. Ikegami, A. and Kato, J.: Immunohistochemical study of cytokeratin expression in subcolumnar reserve cells of the human uterine cervix. *Acta Histochem. Cytochem.* 27; 251-257, 1994.
7. Ivanyi, D., Groeneveld, E., Doornewaard, V.G., Mooi, J.W. and Hageman, C.P.: Keratin subtypes in carcinomas of the uterine cervix: Implications for histogenesis and differential diagnosis. *Cancer Res.* 50; 5143-5152, 1990.
8. Levy, R., Gzernoblisky, B. and Geiger, B.: Subtyping of epithelial cells of normal and metaplastic human uterine cervix, using polypeptide-specific cytokeratin antibodies. *Differentiation* 39; 185-196, 1988.
9. Malecha, J.M. and Miettinen, M.: Patterns of keratin subtypes in normal and abnormal uterine cervical tissues. *Int. J. Gynecol. Pathol.* 11; 24-29, 1992.
10. Moll, R., Schiller, D.L. and Franke, W.W.: Identification of protein IT of the intestinal cytoskeleton as a novel type I cytokeratin with unusual properties and expression patterns. *J. Cell. Biol.* 111; 567-580, 1990.
11. Moll, R., Frank, W.W., Schiller, D.L., Geiger, B. and Krepler, R.: The catalog of human cytokeratins of expression in normal epithelia, tumors and cultured cells. *Cell* 31; 11-24, 1982.
12. Nelson, W.G., Battifora, H., Santana, H. and Sun, T.T.: Specific keratins as molecular markers for neoplasms with a stratified epithelial origin. *Cancer Res.* 44; 1600-1603, 1984.
13. Semdts, F., Ramaekers, F., Robbien, H., Pruszczyński, M. and Vooijis, P.: Basal-cell keratins in cervical reserve cells and a comparison to their expression in cervical intraepithelial neoplasia. *Am. J. Pathol.* 140; 601-612, 1992.
14. Smedts, F., Ramaekers, F., Troyanovsky, S., Pruszczyński, M., Link, M. and Vooijis, P.: Keratin expression in cervical cancer. *Am. J. Pathol.* 141; 497-511, 1992.
15. Smedts, F., Ramaekers, F., Robbien, H., Pruszczyński, M., Muijen, G. and Vooijis, P.: Changing patterns of keratin expression during progression of cervical intraepithelial neoplasia. *Am. J. Pathol.* 136; 657-668; 1990.
16. Weikel, W., Wagner, R. and Moll, R.: Characterization of subcolumnar reserve cells and other epithelia of human uterine cervix. *Virchows Arch. [B]* 54; 98-110, 1987.